

# The Azygos Lobe: An Unusual Anatomical Entity with Unusual Cases

Eurasian Clinical and Analytical Medicine **Review**

## The Azygos Lobe

Rasih Yazkan<sup>1</sup>, Kadir Çeviker<sup>2</sup>, Merve Güblü<sup>3</sup>

<sup>1</sup>Department of Thoracic Surgery

<sup>2</sup>Department of Cardiovascular Surgery

<sup>3</sup>Medical Student, Faculty of Medicine, Süleyman Demirel University, Isparta, Turkey

### Abstract

The knowledge of azygos lobe is important during thoracic surgical procedures. It is a rare anomaly in broncho-pulmonary segmentation due to an unusual course of the azygos vein. There is no a pathological sense alone, if combined with other pathological events should be considered. We aimed to emphasize in this article the formation of the azygos lobe with described together pathologies in the literature.

### Keywords

Azygos Lobe; Azygos Vein; Anatomical

DOI:10.4328/ECAM.55

Received : 22.05.2015

Accepted : 19.06.2015

Published Online : 20.06.2015

Printed Online : 20.06.2015

**Eu Clin Anal Med 2015;3(2):13-5**

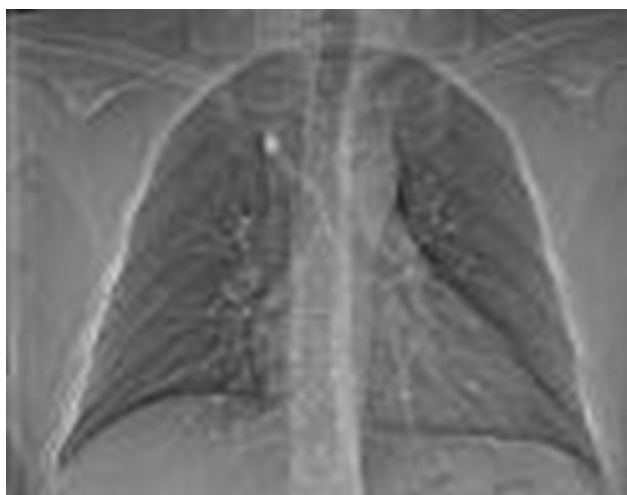
**Corresponding Author:** Rasih Yazkan, Department of Thoracic Surgery, School of Medicine, Süleyman Demirel University, Isparta, Turkey.

**GSM:** +90 505 483 59 61 • **E-Mail:** drrasihyazkan@yahoo.com

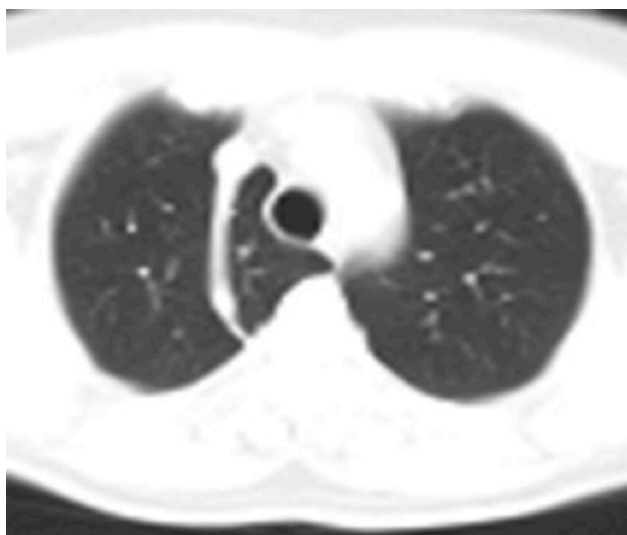
**How to cite this article:** Yazkan R, Çeviker K, Güblü M. The Azygos Lobe: An Unusual Anatomical Entity with Unusual Cases. Eu Clin Anal Med 2015;3(2): 13-5.

The azygos lobe was first described by Wrisberg in 1778 [1,2], the incidence of azygos lobe 0.1 to 1.1% in autopsy series, and 0.01 to 2.6% in radiographic series [1,3]. It is more frequent on the right side (Figure 1,2). An azygos lobe is formed when a precursor of the azygos vein fails to migrate over the apex of the lung during fetal life. The azygos lobe is not a true lobe or accessory lobe because it is not made up of specific bronchopulmonary segments but is formed of varying proportions of 1 or 2 segments of the right upper lobe [4]. Embryologically, a part of upper lobe of the right lung may come to lie medial to the azygos vein, this part is called the azygos lobe [5].

The azygos venous system represents an accessory venous pathway supplying an important collateral circulation between the superior and inferior vena cava [6]. Between the 4th and 6th week of embryonic development, the 4th to the 11th intercostal veins drain into the right supracardinal vein that will form, with the terminal portion of the posterior cardinal vein [1]. The azygos lobe is the result of a defect of medial sliding of the azygos vein towards the right tracheobronchial junction above the apex of the developing lung [1,3]. On the basis of Fleischner's experience, the azygos vein, normally measuring about 0.9 cm, can be seen in 75 % of normal chest Xrays [6,7]. The azygos system is a paired paravertebral venous pathway in the posterior thorax. It originates at the junction of the right ascending lumbar and subcostal veins, entering through the aortic hiatus. It ascends along the anterolateral surface of the thoracic vertebrae and arches ventrally to the right main



**Figure 1.** Posteroanterior Chest X ray: Showing an azygos vein



**Figure 2.** Chest Computed Tomography: Showing an azygos lobe

bronchus at T5-T6, and draining into the SVC. It drains into the right brachiocephalic vein, right subclavian vein, intrapericardial SVC or right atrium more rarely [6,8].

Variations in the azygos system rarely reason symptoms [6]. An azygos lobe is not susceptible to disease. However, multiple authors have reported spontaneous pneumothorax associated within the azygos lobe in adult and pediatric patients. These literatures are; azygos lobe without azygos vein as a sign of previous iatrogenic pneumothorax [9], pneumothorax and mediastinal emphysema due to an air leak from a bulla in an azygos lobe [10], thoracoscopic management of spontaneous pneumothorax due to azygos lobe bullae [11], and spontaneous pneumothorax in a patient with an azygos lobe [12]. The association of an azygos lobe and spontaneous pneumothorax has been rarely reported, there has been speculation that an azygos lobe might have a protective effect against the development of spontaneous pneumothorax. Three mechanisms were proposed: the reflected pleura might be adherent, limiting the size of a potential pneumothorax that would be less easily recognized clinically; the mesoazygos might lessen the mechanical stresses transmitted to the apex of the lung; or the altered anatomy might actually protect against bullae formation [11,12]. Physiologically, there is decreased perfusion and ventilation of the azygos lobe on nuclear studies, thus it is relatively under-inflated. The anatomical explanation for the decreased ventilation is distortion of the bronchi due to bending or kinking by the azygos fissure. On the other hand, this same distortion in bronchial anatomy could predispose the azygos lobe to air trapping with subsequent evolution of emphysema, bronchiectasis, or atelectasis [11].

There are some of the diseases reported in the literatures about the azygos lobe. Azygos lobe associated with esophageal atresia [4], and concomitant occurrence of tracheal bronchus, pulmonary sequestration and azygos lobe [13]. Tracheal bronchus, pulmonary sequestration, and azygos lobes are rare congenital anomalies of the lungs. Although they occur along with various anomalies involving the thoracic cavity [13].

Azygos lobe related tumors are defined in the literatures. Superior sulcus tumor arising in an azygos lobe [14], azygos lobe small cell carcinoma [15], and adenocarcinoma arising in an azygos lobe [16]. Superior sulcus tumors usually arise in the apex of the lung and may invade the brachial plexus, the subclavian vessels, the second and third ribs, the stellate ganglion and adjacent vertebral bodies [14]. The presence of an azygos lobe is assumed to be of little clinical significance. However, neither the surgical/oncological implication of having a tumour confined to an azygos lobe, nor the reasons for rarity of cancer development in this lobe is known, despite its being a common anatomical variance. One theory hypothesizes that this rarity of cancer development results from decreased ventilation of the azygos lobe [16]. While this is a controversial assumption, the ventilation of an azygos lobe may be relatively limited due to constriction by the azygos vein, possibly resulting in less oxygen delivery and particle deposition of carcinogens thereby restricting carcinogenesis within this lobe despite its apparent segmental or subsegmental bronchovascular supply [16].

In conclusion, the knowledge of azygos lobe is important during thoracic surgical procedures. It is a rare anomaly in bronchopulmonary segmentation due to an unusual course of the azygos vein. There is no a pathological sense alone, if combined with other pathological events should be considered.

#### Scientific Responsibility Statement

The authors declare that they are responsible for the article's scientific content including study design, data collection, analysis and interpretation, writing, some of the main line, or all of the preparation and scientific review of the contents and approval of the final version of the article.

**Animal and human rights statement**

All procedures performed in this study were in accordance with the ethical standards of the institutional and/or national research committee and with the 1964 Helsinki declaration and its later amendments or comparable ethical standards. No animal or human studies were carried out by the authors for this article.

**Funding:** None

**Conflict of interest**

None of the authors received any type of financial support that could be considered potential conflict of interest regarding the manuscript or its submission.

**References**

1. Ndiaye A, Ndiaye NB, Ndiaye A, Diop M, Ndiaye JM, Dia A. The azygos lobe: an unusual anatomical observation with pathological and surgical implications. *Anat Sci Int* 2012;87:174-8.
2. Cairney J. The lobe of the azygos vein. *J Anat* 1923;58:54-8.
3. Chiba S, Suzuki T, Takahashi D, Kasai T. An autopsy case of azygos lobe and the extra-pulmonary course of the bronchial veins in man. *Okajimas Folia Anat Jpn* 1990;86(6):313-38.
4. Eradi B, Cusick E. Azygos lobe associated with esophageal atresia: a trap for the unwary. *Journal of Pediatric Surgery* 2005;40: E11 -E12.
5. Salve VT, Atram JS, Mhaske YV. Azygos lobe presenting as right para-tracheal shadow. *Lung India* 2015;32(1):85-6.
6. Piciocchi S, Barone D, Sanna S, Dubini A, Goodman LR, Oboldi D, Et al. The azygos vein pathway: an overview from anatomical variations to pathological changes. *Insights Imaging* 2014; 5:619-28
7. Fleischner FG, Udis SW Dilatation of the azygos vein: a roentgen sign of venous engorgement. *Am J Roentgenol* 1952;67:569-75
8. Dudlak CM, Olson MC, Posniak HV CT. Evaluation of congenital and acquired abnormalities of the azygos system. *Radiographics* 1991;11:233-46
9. Betschart T, Goerres GW. Azygos lobe without azygos vein as a sign of previous iatrogenic pneumothorax: two case reports. *Surg Radiol Anat* 2009;31:559-62
10. Internullo E, Migliore M. Pneumothorax and mediastinal emphysema due to an air leak from a bulla in an azygos lobe. *European Journal of Cardio-thoracic Surgery* 2005;28:641
11. Azoury FM, Sayad P. Thoracoscopic management of spontaneous pneumothorax due to azygos lobe bullae. *Asian Cardiovascular & Thoracic Annals* 2011;19:427-9.
12. Sadikot RT, Cowen ME, Arnold AG. Spontaneous pneumothorax in a patient with an azygos lobe. *Thorax* 1997;52:579-80.
13. Arslan S, Sabancıoğlu V, Akkurt İ. Concomitant occurrence of tracheal bronchus, pulmonary sequestration and azygos lobe. *Türk Göğüs Kalp Damar Cerrahisi Dergisi* 2013;21(2):506-9
14. Delalieux S, Hendriks J, Valcke Y, Somville J, Lauwers P, Van Schil P. Superior sulcus tumor arising in an azygos lobe. *Lung Cancer* 2006; 54: 255-7.
15. Sen S, Barutca S, Meydan N. Azygos lobe small cell carcinoma. *European Journal of Cardio-thoracic Surgery* 2004;26:1041
16. Fukuhara S, Montgomery M, Reyes A. Robot-assisted azygos lobectomy for adenocarcinoma arising in an azygos lobe. *Interactive CardioVascular and Thoracic Surgery* 2013;16:715-7.